

# Late patient-fitted total orbital reconstruction for facial gunshot wound sequelae

### ABSTRACT

Late reconstructions of gunshot wounds (GSWs) in the orbital area are a true challenge to the oral and maxillofacial surgeon. Usually, the wall defects are large in size and commonly present loss of orbital volume, which can cause ocular dystopia. The only exceptions are when there is an explosion of the orbital walls—that is, blow-out fractures. We encountered a patient with a two-year sequelae after GSW in the face that caused the destructed orbit to have a 2.5 bigger size than the contralateral orbit, requiring meticulous planning of a patient-specific implant (PSI) to correctly reconstruct the orbit volume and bone projection. The PSI was developed using titanium and it had three pieces that could reconstruct all four walls of the orbit. After surgery, the patient regained orbital volume and malar projection, allowing him to benefit from facial symmetry. The PSI can be used to reconstruct all the orbital walls in cases of complex bone defects.

**Keywords:** Customized reconstruction, gunshot wound, orbital reconstruction, orbital trauma, patient fitted implant

### INTRODUCTION

The treatment of orbital fractures remains a great challenge to the oral and maxillofacial surgeon because no material or technique is suitable for every patient. Besides, technical demands for surgical repair and related anatomy can cause the reconstruction to be difficult for younger surgeons to perform.

In cases of gunshot wound (GSW) to the face, there are controversies about the closed treatment and late reconstruction, or early open reduction and tissue reconstruction. Late reconstructions are advocated because of minor incidence of infection and benefits of closed treatment.<sup>[1]</sup> Open reductions and early treatment provide better functional and esthetics results.<sup>[2]</sup>

Converse *et al.*<sup>[3]</sup> pointed out the need for orbital floor fracture graft reconstruction to regain orbital volume and avoid enophthalmos. Manson *et al.*<sup>[4]</sup> suggested that the form and position of the implant or graft is more important than the orbital volume, emphasizing that osseous floor anatomy is necessary to provide globe support. More recently, surgical

advancements such as the usage of surgical virtual planning, patient-specific implants (PSI), surgical navigation and intraoperative CT had become available.<sup>[5]</sup>


In this paper, we present an alternative for total orbital reconstruction using 3D-customized implant of a patient who was a victim of a GSW to the face.

**LEONARDO A. P. F. PINTO<sup>1,2</sup>, BERNARDO C. LIMA<sup>3</sup>, GIULIANNA L. PINHEIRO<sup>4</sup>, GUSTAVO G. N. RODRIGUES<sup>2</sup>**

<sup>1</sup>Oral and Maxillofacial Surgery Service, Clementino Fraga Filho University Hospital, Federal University of Rio de Janeiro, Rio de Janeiro, RJ, <sup>2</sup>Centro de Tratamento da Face, Rio de Janeiro, RJ, <sup>3</sup>Hospital da Boca, Santa Casa da Misericórdia do Rio de Janeiro, Rio de Janeiro, RJ, <sup>4</sup>Master Student in Dental Clinics, Dental School, Federal University of Rio de Janeiro, Rio de Janeiro, RJ, Brazil

**Address for correspondence:** Dr. Bernardo C. Lima, Hospital da Boca, Santa Casa da Misericórdia do Rio de Janeiro, Rua Santa Luzia, 206, Centro, Rio de Janeiro, RJ – 20020-022, Brazil.  
E-mail: drbernardoclima@gmail.com

**Received:** 27 May 2022, **Revised:** 21 July 2022, **Accepted:** 22 July 2022, **Published:** 13 July 2023

Access this article online	
<b>Website:</b> www.njms.in	<b>Quick Response Code</b> 
<b>DOI:</b> 10.4103/njms.njms_85_22	

This is an open access journal, and articles are distributed under the terms of the Creative Commons Attribution-NonCommercial-ShareAlike 4.0 License, which allows others to remix, tweak, and build upon the work non-commercially, as long as appropriate credit is given and the new creations are licensed under the identical terms.

**For reprints contact:** WKHLRPMedknow\_reprints@wolterskluwer.com

**How to cite this article:** Pinto LA, Lima BC, Pinheiro GL, Rodrigues GG. Late patient-fitted total orbital reconstruction for facial gunshot wound sequelae. *Natl J Maxillofac Surg* 2023;14:326-9.

## CASE REPORT

A 30-year-old, Caucasian male attended the outpatient facility with a history of attempt of robbery two years before and suffering a GSW to the face and hand. The projectile entered in the left orbit, causing amaurosis and facial disfiguration of the patient [Figure 1]. At the time, no surgical intervention for orbital reconstruction was performed—only globe evisceration for posterior ocular prosthesis. A facial CT scan was performed to better understand the reconstruction needs. The left orbital volume was  $2.5 \times$  bigger than the right orbit, with presence of many projectile artefacts [Figure 2]. Reconstruction with titanium meshes was considered, but because of the huge discrepancy between the orbits, we decided to design a titanium PSI (Artfix by Enterprises®, Paraná, Brazil) for reconstruction of all the orbital walls, providing better functional and esthetic results. The implant was divided into three parts: one to reconstruct the medial wall and orbital floor (1); another to reconstruct the orbital roof (2); and the third for the lateral wall (3). The medial/floor part had a hole that would allow the insertion of the medial canthal ligament. The implants were developed using the mirroring technique, allowing the orbits to have the same volume. After computer design, the prosthesis

was evaluated by means of finite element in which the Von Mises analysis was performed for the implants and fixation screws [Figure 3]. After that, the prosthesis was placed by using two approaches: an extended infra-orbital approach for medial wall/floor and lateral wall (1 and 3) implant placement; and a bicoronal approach for roof (2) implant placement and screw installation of all the three implants [Figures 4 and 5]. Twenty-three screws were used to correctly place the implants. Postoperative computed tomography (CT) showed a correct placement, restoring the orbital volume and malar projection [Figure 6]. The patient is currently on follow-up for a year with no signs of infection, implant rejection, or exposure [Figure 7]. The patient will now undergo reconstruction of the eyelids with a plastic surgeon in order to correct the soft tissue retraction common in gunshot wounds and placement of the prosthetic globe.

## DISCUSSION

Wolff *et al.*<sup>[6]</sup> described the challenges of late orbital reconstruction. They emphasized the importance of knowing the correct bone defect for proper deformity treatment. They also described a case of a blowout fracture reconstruction using a computer-aided design (CAD) implant, justified by the easier placement of this implant when compared to the stock titanium meshes that are designed for average anatomy but not for average defects, becoming very hard to its use in major defects and late reconstruction. U *et al.*<sup>[7]</sup> performed

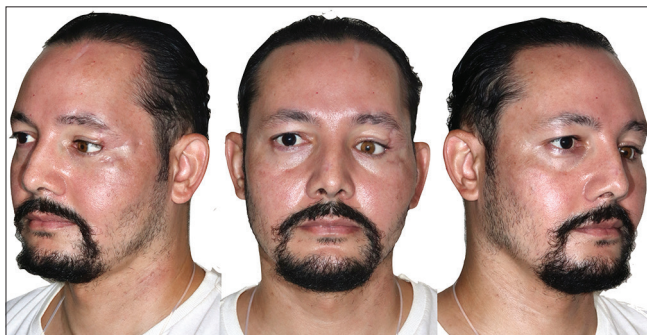

Figure 1: Frontal and oblique view of the patient face showing disfiguration and scar formation from the GSW in the left orbit region

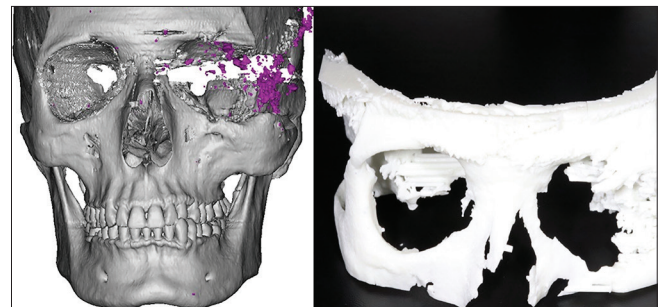


Figure 2: CT scan 3D reconstruction and stereolithographic 3D model from the patient with the difference from the right to the left orbit. Left orbit was  $2.5 \times$  greater than the right one

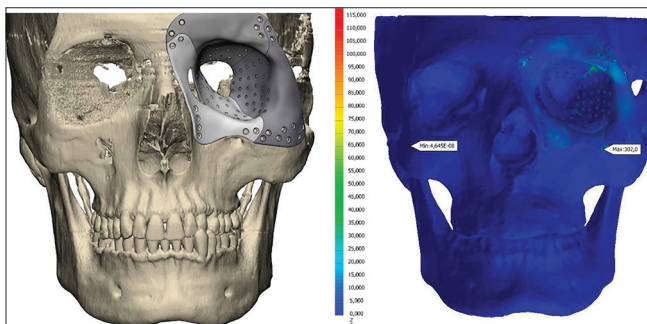


Figure 3: Virtual design of the total orbit PSI using mirroring technique. Right and left orbit have the same volume and size. Note that it is divided into three pieces that together reconstruct all four orbital walls. It is possible to see the 23 roles for fixation screws and their position to hold the PSI in the bone. Von Mises finite element analysis of the PSI was done.

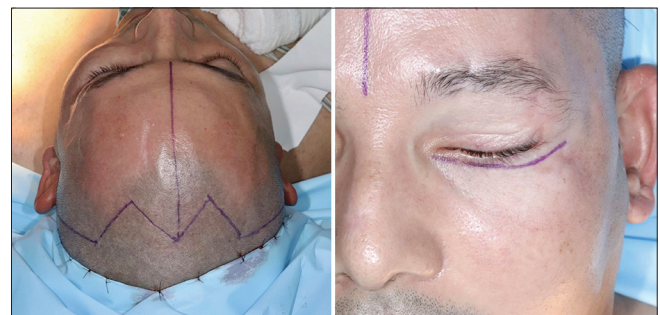

Figure 4: Marking of the bicoronal and infraorbital surgical approaches

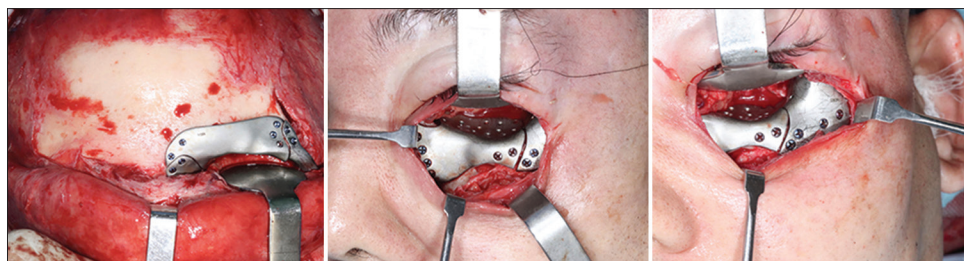


Figure 5: PSI components placed reconstructing the four walls of the orbit

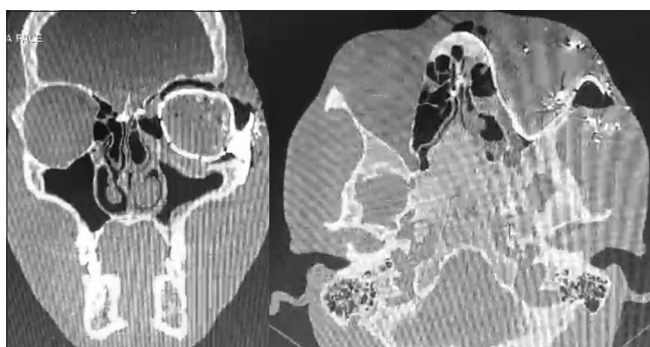

Figure 6: Immediate postoperative CT. Note the correct volume, size and height of the reconstructed orbit compared to the contralateral orbit

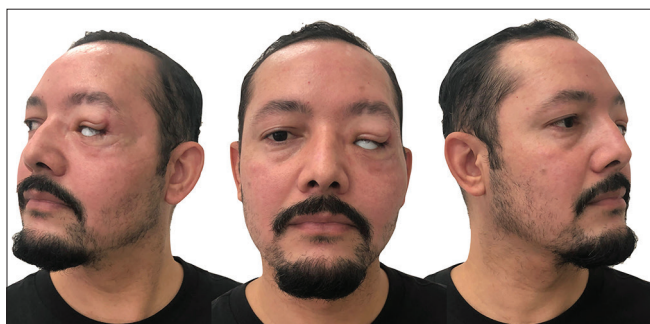

Figure 7: Frontal and oblique postoperative view of the patient

a late reconstruction using a CAD titanium mesh for medial and floor reconstruction to treat binocular diplopia.

Schön *et al.*<sup>[8]</sup> were the first to describe the use of PSI in orbital reconstruction. They used this technique for 19 large orbital defects, obtaining good bone contour, without diplopia or dystopia. After that, Mustafa *et al.*<sup>[9]</sup> reviewed a series of 22 cases treated with customized titanium implants. They printed a stereolithographic 3D model of the orbits for pre-shaping and manufacturing of the titanium mesh pre surgery.

Other authors published techniques for orbital reconstruction using 3D-printed titanium implants. Gander *et al.*<sup>[10]</sup> presented 12 patients treated with PSI for reconstruction of the orbital floor and wall fractures. They emphasized that there was no need for adjustments of the PSI when the implants were

meticulously planned. Baumann *et al.*<sup>[11]</sup> presented late reconstructions with PSI in six patients, all with diplopia or mobility limitations and enophthalmos. Four of them received a poly-ether-ether-ketone (PEEK) PSI and two received titanium mesh PSI. Both types were placed using intraoperative navigation to correctly position the implants. Tarsitano *et al.*<sup>[12]</sup> used the mirroring technique to produce a PSI titanium mesh for late reconstruction of the medial wall and orbital floor defects in seven patients.

Until the present moment, there have been no reports of total reconstruction of the orbit for trauma sequelae. Recently, Sabelis *et al.*<sup>[13]</sup> described the use of PSI for total reconstruction in a case of spheno-orbital meningioma resection sequelae. Ruiters and Mombaerts reviewed the applications of 3D printing technology for orbital defect reconstructions. They considered that PSI would be the gold-standard for large defects. That is because the PSI allows for more accurate positioning and fitting compared to stock implants, has round edges that prevent soft tissue entrapment; is fast and easy to install, and its rigidity prevents bending during placement.<sup>[14]</sup>

Other authors also proposed the use of biomaterials for late orbital reconstruction, such as ultra-high weight polyethylene (UHWPE)—commonly used to build mandibular fossa in temporomandibular joint total joint replacement (TMJ TJR)—UV curable plastic, and PEEK. They all obtained surgical success. Bourry *et al.*<sup>[15]</sup> performed a meta-analysis to evaluate the clinical efficacy of materials used for orbital reconstruction. They concluded that P[L/DL] LA (polymer of L-lactic acid and DL-lactic acid) and PDS (polydioxanone) are best used for small and intermediate defects, whereas porous polyethylene and titanium are best for large defects.

## CONCLUSIONS

This paper presented a case where a titanium PSI was developed to reconstruct all four orbital walls for the management of trauma sequelae, and restoring the correct volume and projection, something not previously reported in literature.

### Declaration of patient consent

The authors certify that they have obtained all appropriate patient consent forms. In the form, the patient(s) has/have given his/her/their consent for his/her/their images and other clinical information to be reported in the journal. The patients understand that their names and initials will not be published and due efforts will be made to conceal their identity, but anonymity cannot be guaranteed.

### Informed consent

Written, informed consent was obtained from patient.

### Financial support and sponsorship

Nil.

### Conflicts of interest

There are no conflicts of interest.

### REFERENCES

1. Deveci M, Sengencer M, Selmanpakoglu M. Reconstruction of gunshot wounds of the face. *Gazi Med J* 1998;9:47-56.
2. Siberchicot F, Pinsolle J, Majoufre C, Ballanger A, Gomez D, Caix P. Traumatismes faciaux par arme de chasse à canon lisse. Analyse d'une série de 165 cas et réévaluation du traitement primaire [Gunshot injuries of the face. Analysis of 165 cases and reevaluation of the primary treatment]. *Ann Chir Plast Esthet* 1998;43:132-40. French. Erratum in: *Ann Chir Plast Esthet* 1998;43:286.
3. Converse JM, Cole G, Smith B. Late treatment of blowout fracture of the floor of the orbit. A case report. *Probl Sovrem Neurokhirurgii* 1961;28:183-91.
4. Manson PN, Clifford CM, Su CT, Iliff NT, Morgan R. Mechanisms of global support and posttraumatic enophthalmos: I. The anatomy of the ligament sling and its relation to intramuscular cone orbital fat. *Plast Reconstr Surg* 1986;77:193-202.
5. Schramm A, Suarez-Cunqueiro MM, Rücker M, Kokemueller H, Bormann KH, Metzger MC, Gellrich NC. Computer-assisted therapy in orbital and mid-facial reconstructions. *Int J Med Robot* 2009;5:111-24.
6. Wolff J, Sándor GK, Pyysalo M, Miettinen A, Koivumäki AV, Kainulainen VT. Late reconstruction of orbital and naso-orbital deformities. *Oral Maxillofac Surg Clin North Am* 2013;25:683-95.
7. U V, Mehrotra D, Dichen, Anand V, Howlader D. Three-dimensional reconstruction of late post traumatic orbital wall defects by customized implants using CAD-CAM, 3D stereolithographic models: A case report. *J Oral Biol Craniofac Res* 2017;7:212-8.
8. Schön R, Metzger MC, Zizelmann C, Weyer N, Schmelzeisen R. Individually preformed titanium mesh implants for a true-to-original repair of orbital fractures. *Int J Oral Maxillofac Surg* 2006;35:990-5.
9. Mustafa SF, Evans PL, Bocca A, Patton DW, Sugar AW, Baxter PW. Customized titanium reconstruction of post-traumatic orbital wall defects: A review of 22 cases. *Int J Oral Maxillofac Surg* 2011;40:1357-62.
10. Gander T, Essig H, Metzler P, Lindhorst D, Dubois L, Rücker M, et al. Patient specific implants (PSI) in reconstruction of orbital floor and wall fractures. *J Craniomaxillofac Surg* 2015;43:126-30.
11. Baumann A, Sinko K, Dorner G. Late reconstruction of the orbit with patient-specific implants using computer-aided planning and navigation. *J Oral Maxillofac Surg* 2015;73 (12 Suppl):S101-6.
12. Tarsitano A, Badiali G, Pizzigallo A, Marchetti C. Orbital reconstruction: patient-specific orbital floor reconstruction using a mirroring technique and a customized titanium mesh. *J Craniofac Surg* 2016;27:1822-5.
13. Sabelis JF, Youssef SALY, Hoefnagels FWA, Becking AG, Schreurs R, Dubois L. Technical note on three- and four-wall orbital reconstructions with patient-specific implants. *J Craniofac Surg* 2021. doi: 10.1097/SCS.00000000000008303.
14. Ruiters S, Mombaerts I. Applications of three-dimensional printing in orbital diseases and disorders. *Curr Opin Ophthalmol* 2019;30:372-9.
15. Bourry M, Hardouin JB, Fauvel F, Corre P, Lebranchu P, Bertin H. Clinical evaluation of the efficacy of materials used for primary reconstruction of orbital floor defects: Meta-analysis. *Head Neck* 2021;43:679-90.